

MINERAL TRIOXIDE AGGREGATE AS A PULPOTOMY AGENT IN IMMATURE TOOTH : A CASE REPORT

Dr. Mehendi Tirkey*, Dr. Mishal Muhammed Haris**
 Dr. Monideepa Mitra***, Dr. Archana Venugopal****
 Dr. Shreyasi Chakraborty*****, Dr. Pradip Kumar Mandal*

ABSTRACT

This case report presents the management of a traumatized immature permanent maxillary central incisor by performing vital pulp therapy with mineral trioxide aggregate as the pulpotomy agent. Satisfactory results were determined over the parameters such as increase in root length, formation of dentinal bridge, absence of periapical radiolucency, intact lamina dura, all of which confirmed with radiographs during regular follow-ups till 9 months. Hence MTA pulpotomy thus performed can be considered as successful and considered as a viable treatment plan for future cases.

KEY WORDS

mineral trioxide aggregate, MTA, pulpotomy, vital pulp therapy

ABOUT THE AUTHORS

*Assistant Professor

** 3rd year Post Graduate Trainee

*** 1st year Post Graduate Trainee

**** 2nd year Post Graduate Trainee

***** Associate Professor

Department of Pedodontics and Preventive Dentistry
 Dr. R. Ahmed Dental College and Hospital

CORRESPONDING AUTHOR

Dr. Mishal Muhammed Haris

3rd year Post Graduate Trainee

Department of Pedodontics and Preventive Dentistry
 Dr. R. Ahmed Dental College and Hospital

INTRODUCTION

Maintaining the vitality of teeth that have been injured or exposed is a key objective in the field of endodontics. For immature permanent teeth with exposed pulps, the preferred treatment methods are partial pulpotomy (Cvek pulpotomy) and deep (cervical) pulpotomy^{1,2}. These techniques can preserve pulp vitality and facilitate the continued development of the tooth root, along with the formation of a hard tissue bridge over the exposed pulp surface³.

In recent years, MTA has been commonly used for pulpotomy in permanent teeth with symptoms of reversible and irreversible pulpitis, as well as in complicated crown fractures of immature and mature teeth.

CASE REPORT

An 8 years old girl reported to the outdoor clinic of Paediatric and Preventive Dentistry Department with the chief complaints of fractured maxillary permanent left central incisor. History revealed trauma to the tooth 24 hours prior. On examination, an Ellis class III fracture with clinical pulp involvement was seen with the fractured crown part still hanging (Figure 1). The patient experienced pain on stimulus. The exposed pulp was bright red in colour, which was an indication of patent blood supply to the pulp. The tooth responded normally to the electric pulp testing that was performed on the labial surface, which signified the healthy status of the pulp. Hence a partial pulpotomy procedure was planned with MTA. Preoperative radiograph was taken to confirm the developmental stage of the tooth and extent of fracture (Figure 2).

The tooth was anesthetized with local infiltration of 2ml lignocaine (1:200000 adrenaline). The fractured crown part was reattached with direct composite resin (Figure 3). The tooth was disinfected with chlorhexidine. The exposed pulp and surrounding dentin were flushed clean with isotonic saline solution. The superficial layer of the exposed pulp and the surrounding tissue were excised to a depth of 2 mm using a sharp spoon excavator, with a light touch. The surface of the remaining pulp was irrigated with isotonic saline

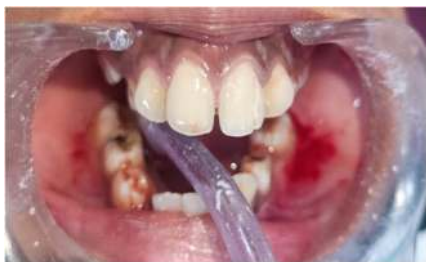

Figure 1- Preoperative photograph showing Ellis Class III fracture in permanent upper left maxillary incisor

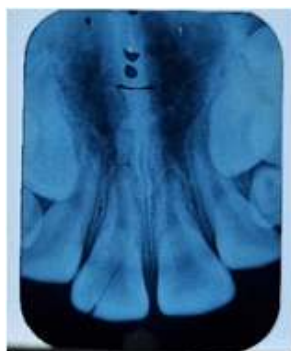

Figure 2- Pre operative radiograph showing opex apex in the fractured tooth

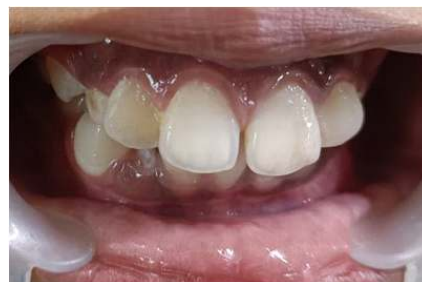

Figure 3- After reattachment of the fractured tooth segment

and the bleeding was arrested with help of sterile moist cotton pellet. White MTA was freshly mixed and placed over the exposed pulp, following which a saline-soaked cotton pellet was placed over the MTA for 45 minutes to allow it to set. The exposed dentin and MTA were both sealed with temporary restorative material (3M™ Cavit™).

RESULTS

On finding the tooth to be asymptomatic at one week follow up Glass ionomer cement restoration was done over the access cavity.

Periodic follow ups were done at 2 weeks, 3 months, 6 months and 9 months (Figure 4) interval. The tooth remained asymptomatic throughout this period. The intra-oral periapical radiograph of the tooth was also taken; the periapical region appeared normal (lamina dura was intact without any periapical changes).

DISCUSSION

When a clinician encounters a tooth with pulp exposure, several factors influence the treatment decision. Partial pulpotomies after complicated crown fractures have a high success rate of 96%, as reported by Cvek et al. One advantage of partial pulpotomy over cervical or complete pulpotomy is the preservation of the coronal pulp tissue, which has better healing potential and can maintain the physiological deposition of dentin. However, the risk of pulp necrosis or calcific metamorphosis remains, and periodic follow-ups are necessary. Age is also an important criterion for selecting patients for vital pulp therapy, as older pulps are more fibrous, less cellular, and may have reduced blood supply, which can affect the treatment outcome.

Calcium hydroxide (CH) materials have been widely used to treat exposed pulp, due to their short-term antimicrobial effects and ability to stimulate the formation of a hard tissue bridge⁴. The coagulation necrosis produced by the release of hydroxyl ions

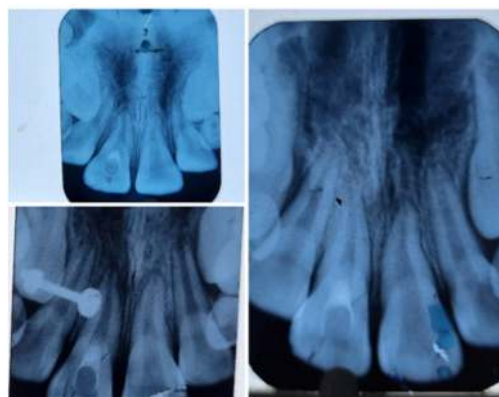


Figure 4- IOPARs taken on follow up at 3, 6 and 9 months post operatively

from CH materials is thought to promote bridge formation at the site of exposure⁴. Higher calcium levels and alkalinity provided by CH materials have also been shown to increase the expression of bone morphogenetic protein-2 (BMP-2) and the solubilization of tissue growth factor- β 1 (TGF- β 1) from dentin tissue⁵. These molecules may play a role in the formation of the dentin bridge⁶. Additionally, calcium ions in association with necrotic cell debris may contribute to the formation of dystrophic calcification, which can initiate the differentiation of odontoblast-like cells⁷.

Mineral trioxide aggregate (MTA) is an alternative to CH materials for direct pulp capping and pulpotomy treatments. CH is one of the major hydration products during the setting reactions of MTA and is released from MTA in decreasing rates over time⁸. Calcium and hydroxyl ion release from MTA may be important for pulp tissue healing and the formation of a hard tissue bridge, similar to CH materials⁶. MTA has been shown to have better sealing ability as a root-end filling material compared to conventional zinc-oxide eugenol cements, and it can induce the formation of more and thicker dentin bridges than CH⁹. Clinical reports have demonstrated successful outcomes, such as the preservation of pulp vitality over longer periods and the continuation of root formation, when using MTA as a pulpotomy agent¹⁰.

Studies on animal models have shown that the hard tissue bridge formed under calcium hydroxide has imperfections and tunnel defects that may allow bacterial leakage, whereas the bridge formed after MTA placement is complete and free of defects. In human teeth, it has been reported that at six months, a thicker dentin bridge (0.43 mm) is evident with MTA, compared to calcium hydroxide (0.15 mm), which does not have an odontoblastic layer¹¹. Recent studies by Accorinte et al. have shown that pulp healing with calcium hydroxide is slower than with MTA when used as a pulp capping agent in human teeth¹². Sarkar et al. have also proven that MTA can bond chemically to dentin by a diffusion-controlled reaction between the apatite layer of MTA and dentin¹³. Chen et al. have shown that MTA is biocompatible and has osteoconduction effects on bone cells¹⁴.

In our case, we used white MTA in the anterior region for aesthetic reasons. A waiting period of 45 minutes was followed to allow the setting of MTA before the placement of GIC, as recommended by Nandini et al¹⁵.

CONCLUSION

In conclusion, for recently traumatized teeth with pulp exposure, partial pulpotomy within 24-48 hours after the injury can act as a permanent restorative procedure without the need for endodontic treatment, provided a bacteria-tight seal is obtained. The age of the patient is also an important factor to consider when selecting patients for vital pulp therapy.

It is possible to utilize Mineral Trioxide Aggregate (MTA) as a substitute material for pulpotomy procedures in teeth with incomplete development and exposed pulp tissue. This approach can encourage the healing of the pulp and the formation of a dentin bridge, as well as the full development of the root. However, a significant clinical issue that may arise from an MTA pulpotomy is tooth discoloration.

REFERENCES

1. Cvek M. A clinical report on partial pulpotomy and capping with calcium hydroxide in permanent incisors with complicated crown fracture. *J Endod* 1978;Aug;4(8):232-7.
2. Çalışkan MK. Success of pulpotomy in the management of hyperplastic pulpitis. *Int Endod J* 1993;26:142-148.
3. Cvek M. Endodontic management and the use of calcium hydroxide in traumatized permanent teeth. In: Andreasen JO, Andreasen FM, Andreasen L eds. *Textbook and color atlas of traumatic injuries to the teeth*. 4th ed. Copenhagen, Blackwell Munksgaard, 2007:605
4. Schröder U. Effects of calcium hydroxide-containing pulp capping agents on pulp cell migration proliferation and differentiation. *J Dent Res* 1985;64:541-548.
5. Graham L, Cooper PR, Cassidy N, Nor JE, Sloan AJ, Smith AJ. The effect of calcium hydroxide on solubilization of bio-active dentin matrix components. *Biomaterials* 2006;27:2865-2873.
6. Rashid F, Shiba H, Mizuno N, Mouri Y, Fujita T, Shinohara H, Ogawa T, Kawaguchi H, Kurihara H. The effect of extracellular calcium ion on gene expression of bone-related proteins in human pulp cells. *J Endod* 2003;29:104-107.
7. Yoshida K, Yoshida N, Nakamura H, Iwaku M, Ozawa H. Immunolocalization of fibronectin during reparative dentinogenesis in human teeth after pulp capping with calcium hydroxide. *J Dent Res* 1996;75:1590-1597.
8. Chedella SCV, Berzins DW. A differential scanning calorimetry study of the setting reaction of MTA. *Int Endod J* 2010;43:509-518
9. Gondim E Jr, Kim S, de Souza-Filho FJ. An investigation of microleakage from root-end fillings in ultrasonic retrograde cavities with or without finishing: a quantitative analysis. *Oral Surg Oral Med Oral Pathol Oral Radiol Endod* 2005;99:755-760
10. Karabucak B, Li D, Lim J, Iqbal M. Vital pulp therapy with mineral trioxide aggregate. *Dent Traumatol* 2005;21: 240- 243.
11. Aeinehchi M, Eslami B, Ghanbariha M, Saffar AS. Mineral trioxide aggregate (MTA) and calcium hydroxide as pulp-capping agents in human teeth: a preliminary report. *Int Endod J*. 2003;36:225-3.
12. Accorinte Mde L, Holland R, Reis A, Bortoluzzi MC, Murata SS, Dezan E Jr, Souza V, Alessandro LD. Evaluation of mineral trioxide aggregate and calcium hydroxide cement as pulp-capping agents in human teeth. *J Endod*. 2008 Jan;34(1):1-6.
13. Sarkar NK, Caicedo R, Ritwik P, Moiseyeva R, Kawashima I. Physicochemical basis of the biologic properties of mineral trioxide aggregate. *J Endod*. 2005;31:97-100.
14. Chen CL, Huang TH, Ding SJ, Shie MY, Kao CT. Comparison of calcium and silicate cement and mineral trioxide aggregate biologic effects and bone markers expression in MG63 cells. *J Endod*. 2009;35:682-5.
15. Nandini S, Ballal S, Kandaswamy D. Influence of glass-ionomer cement on the interface and setting reaction of mineral trioxide aggregate when used as a furcal repair material using laser Raman spectroscopic analysis. *J Endod*. 2007; 33:167-72.