

ORTHODONTIC MANAGEMENT OF UNILATERAL MAXILLARY IMPACTED CANINE - CASE REPORT

Dr. Muhammed Mahshook AP *, Dr. Ankita Das*, Dr. Rakesh R**
Prof.(Dr)Rupa Ghosh***, Dr. Ekramur Rahman****

ABSTRACT

Maxillary canines are important for esthetic and proper function. Orthodontic treatment of impacted maxillary canines is a challenging task and necessitates complicated and prolonged treatment. It needs a multidisciplinary team including orthodontists, oral surgeons, and periodontists. In order to attain better treatment prognosis and stability in management of impacted canines, precise application of biomechanics and force levels are essential considerations. This case report describes surgical exposure followed by orthodontic treatment for correction of unilateral maxillary right canine impaction in a 22-year-old female patient.

KEY WORDS

Impacted canine, Surgical exposure, torquing spring

ABOUT THE AUTHORS

*3rd year PGT,

Dept of Orthodontics & Dentofacial Orthopaedics
Dr. R. Ahmed Dental College and Hospital, Kolkata

**Consulting orthodontist in private practice, Kerala

***HOD, Professor and PG Guide

Dept of Orthodontics & Dentofacial Orthopaedics
Dr. R. Ahmed Dental College and Hospital, Kolkata

****2nd year PGT,

Dept of Orthodontics & Dentofacial Orthopaedics
Dr. R. Ahmed Dental College and Hospital, Kolkata

CORRESPONDING AUTHOR

Dr. Muhammed Mahshook AP

3rd year PGT

Dept of Orthodontics & Dentofacial Orthopaedics

Dr. R. Ahmed Dental College & Hospital, Kolkata

e-mail: makppl123@gmail.com

INTRODUCTION

The maxillary canine, also known as the "corner teeth" is a vital component of the upper dental arch, playing a pivotal role in aesthetics, function, arch development, and occlusion¹. The presence of an impacted maxillary canine is a relatively common and a clinically challenging condition in the field of orthodontics. The maxillary canine is the second most impacted tooth after the third molar,² the longest path of eruption and long duration of development play an important role in its impaction. Incidence of canine impaction in the maxilla is found to be twice that of mandibular impactions³. Impaction can occur either in unilateral or bilateral pattern. Of all patients, only 8% shows bilateral canine impactions.⁴ Incidence has correlation with gender predilection also which is twice common in females than males.⁴ The palatal displacement of canine is twice more common than buccal displacement. But in clinical practice, buccally impacted canines are more common.⁵

Even though the exact etiology of impacted canines is unknown, it can occur due to various factors. Several etiologic factors for canine impactions have been proposed, it may be localized, systemic, or genetic⁶, arch length discrepancy is thought to be a primary etiologic factor for labially impacted canines.⁷ A multi-factorial genetic pattern of inheritance for the anomaly was suggested by Peck and Peck⁸. Prinin et al reported genetic and incisor-premolar hypodontia and peg shaped lateral incisors⁹ associated with impacted canines. According to Baccetti¹⁰ impaction of maxillary canines are genetically associated with anomalies like enamel hypoplasia, infraocclusion of primary molars, aplasia of second premolars, and small maxillary lateral incisors.

Usually localized factors like: (a) tooth size-arch length discrepancies, (b) prolonged retention of the deciduous canine, (c) early loss of the deciduous canine, (d) abnormal position of the tooth bud, (e) the presence of an alveolar cleft, (f) ankylosis, (g) cystic or neoplastic formation, (h) root dilaceration, are the most common causes for canine impactions.

Other anomalies like tooth size, shape, number, and structure; hypoplastic enamel, infra-occluded

primary molars and aplastic second bicuspid^{11,12}. often present with impacted canines.

An impacted canine should be treated either orthodontically or extraction can be considered when successful alignment of teeth is thought to be unlikely. Untreated case of impacted teeth may lead to complications like root resorption of the neighbouring lateral incisor and first premolar, and development of cyst.^{13,14}

The diagnosis of impacted canine is based on both clinical and radiographic examinations.

Clinical examination includes inspection, palpation of canine bulges, mobility of primary canines, abnormality in shape, missing lateral incisors, or less mobility of primary canines¹⁵.

Radiographic imaging, like intraoral periapical radiographs, occlusal radiographs, orthopantomograms, cone-beam computed tomography, etc, can be used for identification, diagnosis, and localization of the impacted canine.

An expertised team of oral surgeon, orthodontist and periodontist is important for early diagnosis and timely treatment which will bring about better prognosis in the management of impacted canines. The most common method in treatment of impacted canines is bonding of attachment on surgically

exposed tooth, followed by orthodontic traction to bring the teeth in to arch.

This is a case report of labially impacted canine in a 22 year old female patient and was treated using MBT system.

CASE REPORT

A 22 year old female patient reported in the Department of Orthodontics & Dentofacial Orthopaedics with a chief complaint of gap between teeth on upper right side and proclined upper and lower front teeth irregularly arranged teeth with a wide gap between anterior two front teeth. History revealed no relevant medical or dental history and no extractions was done in the past.

On Extra oral examination, she had apparently symmetrical face with slight convex profile, euryprosopic facial type. Lips were competent with 0mm inter-labial gap. She has adequate chin and mento-labial sulcus.(Fig1)

On intra-oral examination, patient has wide arch forms in both the maxilla and mandible. All permanent teeth except 13,38. There is a wide gap between 12,14. She had Class I molar and class I canine relationship on left side, anterior crossbite was

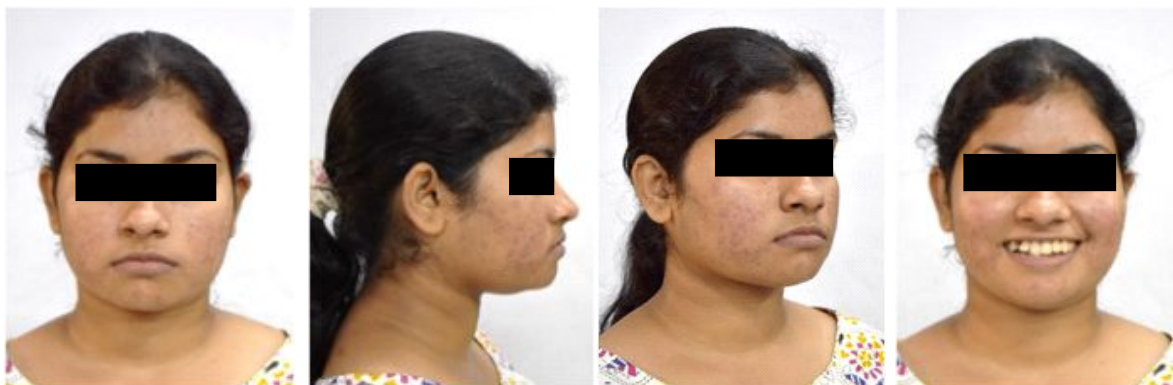

Fig-1

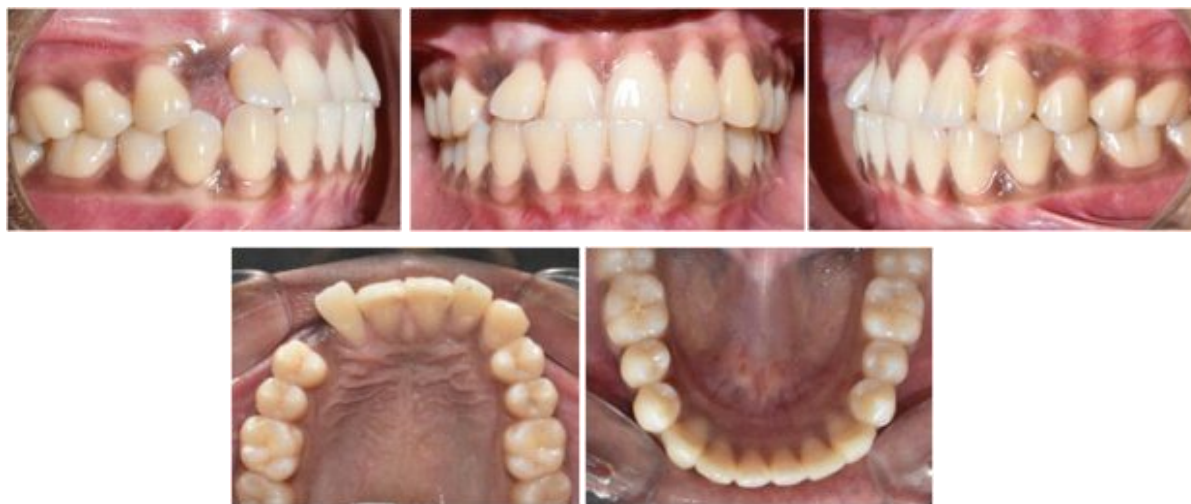

Fig-2

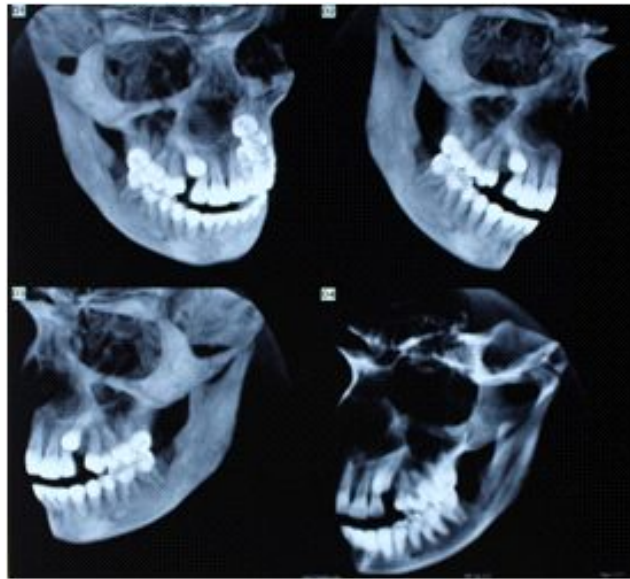
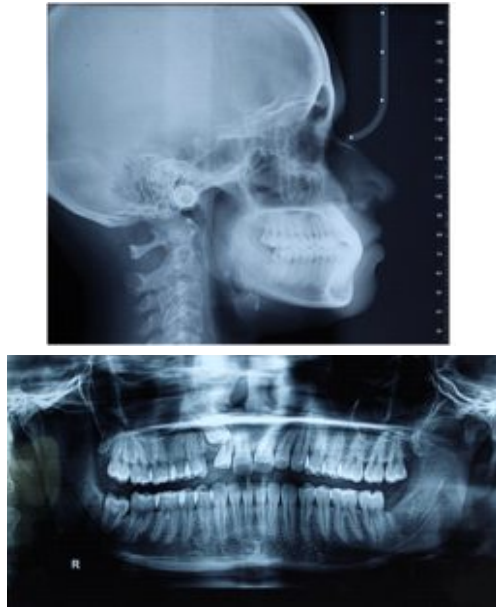


Fig 3

present with overjet of -1mm and overbite of -2.5mm along with mal alignment of right lateral incisor with a bulge present distal to it. There is proclination of both maxillary incisors and mandibular incisors and rotation 33. The upper and lower dental mid line was coincident with the facial midline. (Fig 2)

On Radiographic examination, the OPG and CBCT shows complete permanent dentition with labially impacted upper right maxillary canine, missing 38 and developing 48. (Fig 3)

She was diagnosed as Angles class I malocclusion on class I skeletal bases with horizontal growth pattern, impacted 13, anterior cross bite, with -1mm of overjet and -2.5 mm overjet.

PROBLEMLIST

- Impaction irt 13
- Cross bite 11,21
- Overjet -1 mm
- Overbite -2 mm
- Labially tipped 12,22
- rotation irt33

TREATMENT OBJECTIVES

1. To expose 13 surgically followed by leveling and alignment of 13,
2. To attain class I canine relation.
3. To maintain the class I molar relation
4. To attain class I incisor relation.
5. To attain normal overjet and overbite.
6. To improve the smile and overall appearance.

PROPOSED TREATMENT PLAN

Patient was planned to be treated with non extraction. Dentoalveolar correction is done by MBT (.022x.028 SLOT) Preadjusted Edgewise mechanics after getting consent from patient.

TREATMENT PROGRESS

The brackets were bonded on all teeth in both arches, except on right maxillary canine with bands on the molar. The initial alignment was done using .014 in followed by 0.016 in nickel-titanium wires by engaging wire in all the teeth except for the right maxillary canine. followed by placement of 0.017 in \times 0.025 in nickel-titanium arch wires in both arches. Surgical exposure is done by raising a full thickness mucoperiosteal flap which cover the tooth. After achieving adequate hemostasis an attachment with 0.010 in ligature wire was bonded on the labial surface of the exposed tooth, (Fig 4) the flap is sutured back in position.

Traction is given on 0.017 in \times 0.025 in stainless steel wire with step bend in the canine region on upper arch (Fig 5) After the tooth is visible enough the tooth was bonded. Releveling and realignment phases were done on upper arch.(Fig 6) Additional torque was given for 12&13 by using torquing spring on 0.014 in ss arch wire (Fig 7)

TREATMENT RESULT

The leveling and alignment of labially impacted maxillary canine was done, attained class 1 canine and incisor relation by maintaining class I molar relation. Ideal overjet and overbite were also

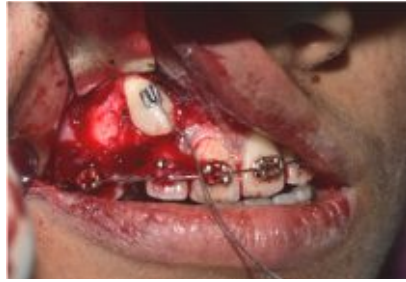

Fig 4

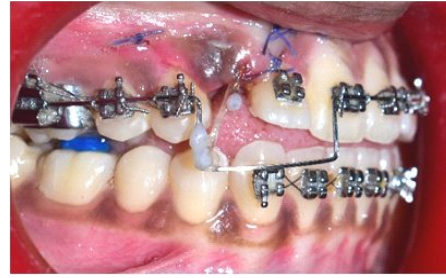


Fig 5

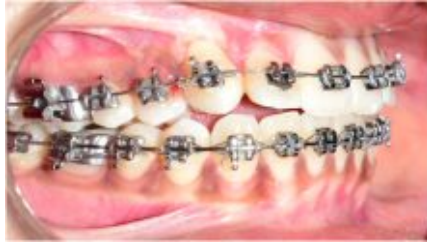

Fig 6

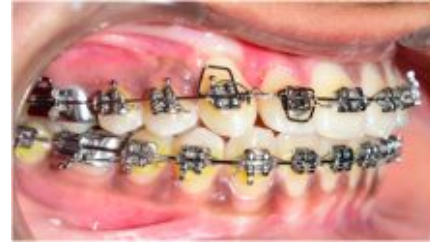

Fig 7

achieved. The treatment goals and objectives were accomplished, and the patient is happy with the final outcome (Fig 8)

DISCUSSION

Diagnosis of impacted maxillary canine done by inspection, palpation, and radiography are three diagnostic methods for impacted canine. Clinical examination involves inspection of lateral incisor

inclination, color and mobility of deciduous canine, agenesis of lateral incisor and presence of bulge. Palpation should be done both buccally and palatally near lateral incisors and first premolar region for presence any bulge or mobility of adjacent teeth. OPG and occlusal radiographs are used to find the position of impacted canine, often assisted by IOPA using same-lingual-opposite-buccal rule. Recent diagnostic aids like CBCT is used to locate the exact position of root and crown of impacted canine in

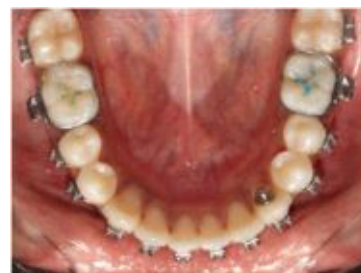
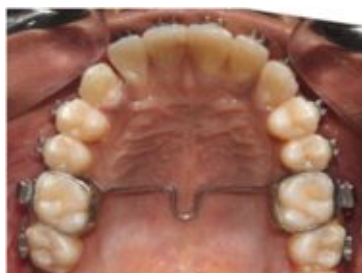
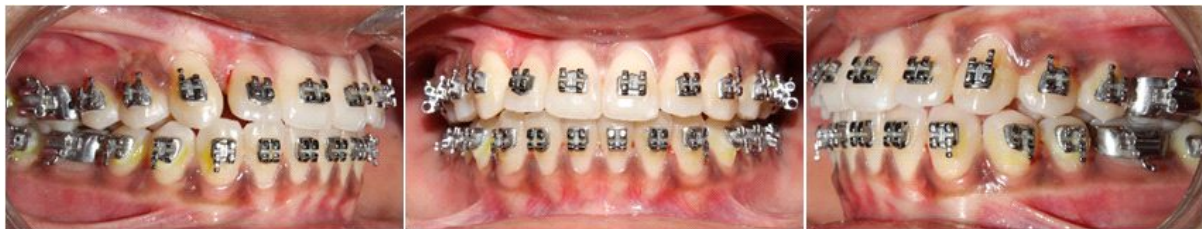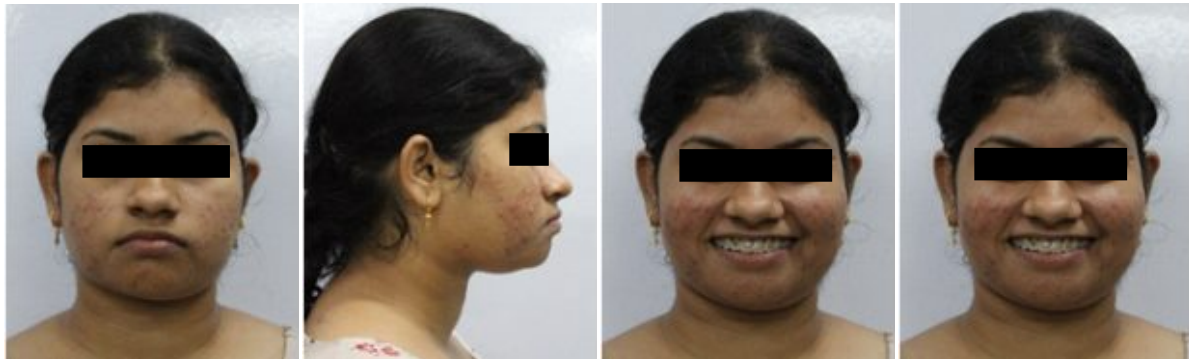Fig 8

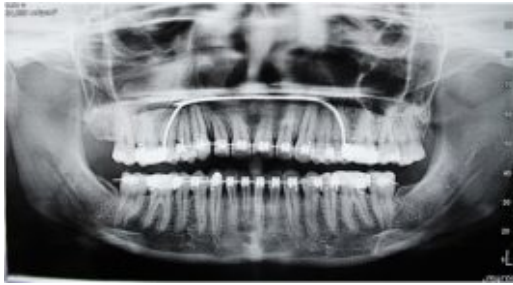
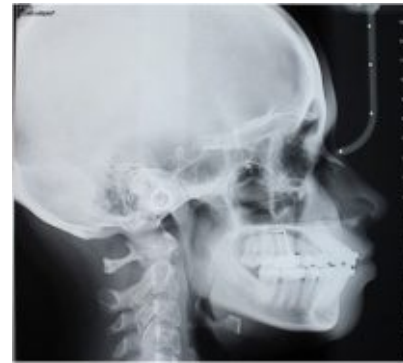
Fig 9



Cephalometric values	PRE	POST
SNA(Degree)	89 ⁰	89 ⁰
SNB(Degree)	90 ⁰	90 ⁰
ANB(Degree)	-1 ⁰	-1 ⁰
WITS	-3mm	-3mm
UI-NA(angular)	33 ⁰	38 ⁰
UI-SN	122 ⁰	126 ⁰
IMPA(Degree)	90 ⁰	101 ⁰
NAper-pt.A	+3.5mm	+4mm
NAper-pog	+4mm	+7mm
FMA	22 ⁰	20 ⁰
LAFH	45 ⁰	49 ⁰
Interincisalangle	113 ⁰	105 ⁰
Y-Axis	59 ⁰	59 ⁰
NasolabialAngle	92 ⁰	90 ⁰

relation to the surrounding structures and also relation with dentition.

The impacted teeth should bring through the attached gingiva and should be placed properly in the alveolar ridge. Improper mechanics causes root resorption, labial movement of teeth, which will bring bony dehiscence and gingival recession.

CONCLUSION

For management of impacted canine the cases should be evaluated in terms of age, crowding, spacing, position and pathology associated with the impacted canine. A detailed investigatory process by using recent diagnostic techniques like CBCT is important it may reveal the etiological factors and make diagnosis and treatment plan easier.

Even though the management of impacted canine is challenging situation in clinical practice, with the help of diagnostic techniques and by applying precise orthodontic biomechanics it is possible to bring the teeth into a aesthetically and functionally acceptable position in the arch.

Patient Consent : Provided.

REFERENCES

1. Bedoya MM, Park JH. A review of the diagnosis and management of impacted maxillary canines. *J Am Dent Assoc* 2009;140:1485-93.
2. Litsas G, Acar A. A review of early displaced maxillary canines: etiology, diagnosis and interceptive treatment. *The open dentistry journals*. 2011;5:39.
3. Yavuz MS, Aras MH, Büyükkurt MC, Tozoglu S. Impacted mandibular canines. *J Contemp Dent Pract* 2007;8:78-85.
4. Bishara SE. Impacted maxillary canines: A review. *Am J Orthod Dentofacial Orthop*. 1992;101:159-71.
5. Ericson S, Kurol J. Early treatment of palatally erupting maxillary canines by extraction of the primary canines. *Eur J Orthod*. 1988;10:283-95
6. Power SM, Short MB. An investigation into the response of palatally displaced canines to the removal of deciduous canines and an assessment of factors contributing to a favourable eruption. *Br J Orthod*. 1993;20:215-23.
7. Mitchell L, editor. *An Introduction to Orthodontics*. 3rd ed. New York: Oxford University Press; 2007. pp. 147-56.
8. Peck S, Peck L. The palatally displaced canine as a dental anomaly of genetic origin. *Angle Orthod* 1994;64:249-56
9. Pirinen S, Arte S, Apajalahti S. Palatal displacement of canine is genetic and related to congenital absence of teeth. *J Dent Res*. 1996;75:1742-1746.
10. Baccetti T. A controlled study of associated dental anomalies. *Angle Orthod*. 1998;68:267-74.
11. Abu-Hussein M, Watted N, Proff P, Watted A. *Clinical Management of Bilateral Impacted Maxillary Canines*. *SRL Dentistry*. 2017;1(1): 001-007.
12. Jacoby H. The etiology of maxillary canine impactions. *Am J Orthod* 1983;84:125-32.
13. Shapira Y, Kuftinec MM. Early diagnosis and interception of potential maxillary canine impaction. *J Am Dent Assoc* 1998; 129: 1450-4.
14. Chaushu S, Bongart M, Aksoy A, Ben-Bassat Y, Becker A. Buccal ectopia of maxillary canines with no crowding. *Am J Orthod Dentofacial Orthop* 2009; 136: 218-23.
15. Becker A, editor. *The orthodontic treatment of impacted teeth*. 2nd ed. Abingdon, Oxon, England: Informa Healthcare; 2007. p. 1-228.