MAXILLECTOMY REPAIRED BY TEMPORALIS MYOFASCIAL FLAP IN A PATIENTS OF ADENOID CYSTIC CARCINOMA OF PALATE

Dr. Subhasish Burman[1], Dr. Jayanta Saha[2], Dr. Soumen Mondal[3]
Dr. Siddhartha Mishra[4], Dr. Mustafizur Rahaman[5], Dr. Sanjoy Roy[6],
Dr. Chandmani Tigga[7], Dr. Malay Bachhar[8], Dr. Divya Chadda[9]

Abstract

Adenoid cystic carcinoma is an uncommon tumour, accounting for about 1 % of all head neck malignancies and about 10 % of all salivary gland tumours. It is the most commonly reported malignant tumours of the minor salivary gland and is one of the most common cancers of major salivary gland (parotid, submandibular gland, minor salivary glands).Adenoid cystic carcinoma is relentlessly growing tumour characterized by perineural invasion and multiple local recurrences. Clinically AdCC is regarded as high grade neoplasm, and consequently the treatment of choice is radical surgical resection and is almost always followed by radiotherapy. Palate is one of the most common site of AdCC. Often after radical surgical resection (maxillectomy) reconstruction of the defect is needed for the rehabilitation. In this present case report surgical management of aAdCC of left side of palate and reconstruction of the post surgical defect is described.

Key Words AdCC, Minor salivary gland, maxillectomy

INTRODUCTION

AdCC was first described by Robin, Lorain, Laboulbene in two articles published in 1853 and 1854 reporting on one parotid and two nasal tumours[1]. In 1856 Billroth suggested the term Cylindroma for this tumour, the current name of "Adenoid cystic carcinoma" was introduced by Spies in 1930. The malignant nature of this tumour was finally established by Dockerty and Mayo[2]. AdCC is most commonly found in the palate followed by the para-nasal sinuses and other sites of the oral cavity[3,4]. AdCC has high propensity for infiltrating to adjacent tissue, especially through perineural invasion so even in resectable AdCC the goal of free margin is often not achieved. Radical wide local excision of the tumour located in palate results in a defect that leads to difficulties in eating, speech of the patient. It is very necessary to rehabilitate the patient after surgery to maintain the various function. There are various options available for reconstruction of the palatal defect such as free flaps and local flaps. Among the local flaps one of the most common flap used for maxillary reconstruction is temporalis myofascial flap. It has its own advantage of being located near to the defect and sufficient bulk and adequate vascular supply. From a functional point of view temporalis myofascial based reconstructive procedure are effective in palatal defect.

ABOUT THE AUTHORS

1. Associate professor and P.G. guide (DEPT. of ORAL AND MAXILLOFACIAL SURGERY, Dr. R. A. D. C. & H, KOLKATA)
(2,3). Clinical tutor (DEPT. of ORAL AND MAXILLOFACIAL SURGERY, Dr. R. A. D. C. & HKOLKATA)
(4,8,9). 2nd year P.G.T. (DEPT. of ORAL AND MAXILLOFACIAL SURGERY, Dr. R. A. D. C .& HKOLKATA)
(5,6,7). 3rd year P.G.T. (DEPT. of ORAL AND MAXILLOFACIAL SURGERY, Dr. R. A. D. C. & HKOLKATA)

All rights reserved

However one must keep in mind that this type of reconstruction can only be used if a resection of the cutaneous tissues and orbital exenteration are not deemed necessary. After maxillectomy the TMF can reach the contralateral palate as well, allowing complete coverage of the hemipalatal defects. The hemicoronal scars provides satisfactory cosmetic results since it starts in the pretragalregion and extends superiorly often within the hairline. In this article a case report about temporalis myofascial flap used to repair the defect after hemimaxillectomy in a adenoid cystic carcinoma patient is described.

CASE REPORT

A 55 years old female patient came to our department with complaint of pain and burning sensation in left side of face and upper jaw since one and half months. On intraoral examination a well-defined, firm , non-fluctuant, non-compressible swelling measuring about 4 cmx 2 cm in size was found in the left side of palate extending from left upper first premolar to tuberosity area. No surface ulceration or pigmentation was present. Swelling was not extending beyond the midpalatine raphe. Adjacent teeth were not mobile and no paraesthesia was present. No palpable cervical lymphnode was present. Incisional biopsy confirmed the swelling as adenoid cystic carcinoma. Contrast enhanced computed tomography of face and neck was done and it revealed the tumour mass extended into the maxillary sinus involving anterior and postero-lateral wall near to invove the pterygoid plate posteriorly. No orbital involvement was noted .

Necessary investigations were done including routine blood tests, tests for coagulopathies, liver function test ,kidney function tests, chest x ray (PA view), ECG was done to assume any comorbidity .

SURGICAL PROCEDURE

A modified weberfergusonincision with Borley's extension was given for total maxillectomy and followed by reconstruction with temporalis myofascial flap [5]. Incision was done with a no 10 blade and scalpel. Deeper tissue dissection was done with electro-cautery blade. Infra-orbital nerve was clamped and resected. Ipsilateral total maxillectomy was done with orbital floor removal without disturbing ligament. Lateral orbital rimwas osteotomized below the whitnall's tubercle, hense the suspensory ligament of eyeball was undisturbed. Medial orbital wall was osteotomized below the medial canthal ligament. Temporalis myo-fascialpedicle flap was raised and positioned into the defect. Surgical site was closed with absorbable suture(vicryl) and skin and scalp margin was apposed

PREOPERATIVE FRONTAL VIEW OF THE PATIENT

INTRA ORAL VIEW

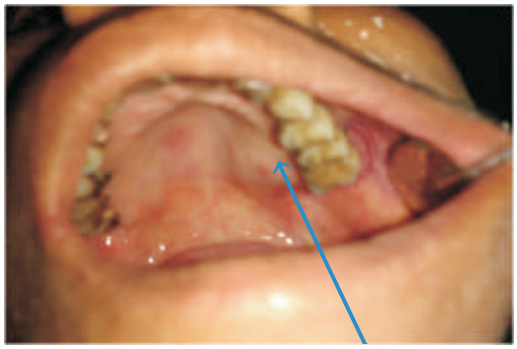

Swelling in the palate

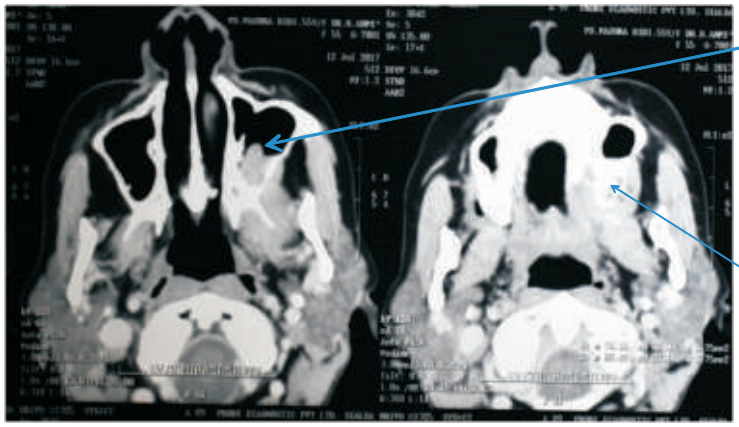

TUMOUR EXTENDING INTO MAXILLARY SINUS

TUMOUR INVOVING THE HARD PALLATE

 All rights reserved

Incision Marking

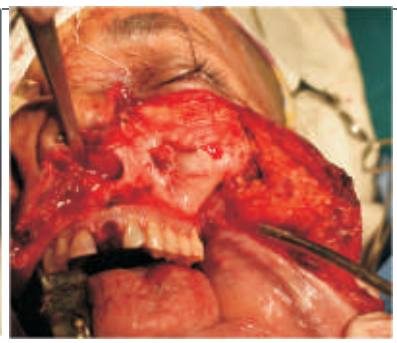

After Exposure Of The Maxilla

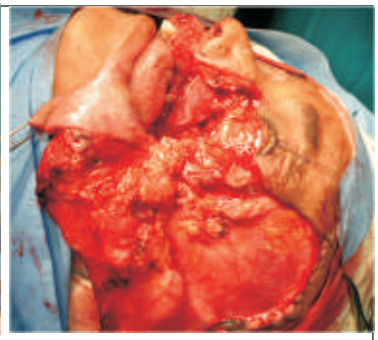

Flap Is Raised To Expose Temporal Area

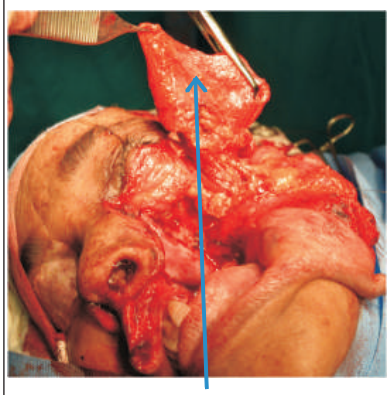

Temporalis Myofascial Flap Is Raised

Resected Specimen

Temoralis Muscle Flap Is Repositioned And Sutured In The Defect

After Completion Of Extra Oral Suturing

After complete closure

One week post op view (Intra oral)

One Week Post Operative View (Temporal Area)

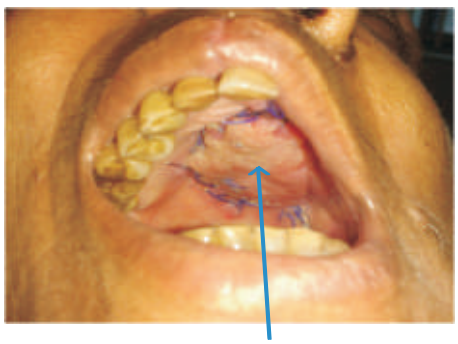

Two Weeks Post Operative View (Intra Oral)

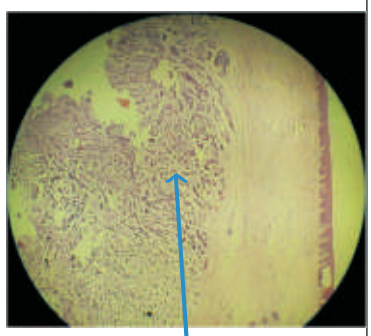

Tumour islands in the connective tissue.

All rights reserved

with non-absorbable suture(nylon).

The resected specimen was sent for histopathological examination.

Postoperative complications included inability to close ipsilateral eyelid completely, and absence of forehead wrinkles during frowning in ipsilateral side.

DISCUSSION

Adenoid cystic carcinoma most often presents a diagnostic and treatment challenge owing to the rarity of the lesion. Most findings regarding ADCC are actually based upon studies with a small number of patients and there is a need for further information regarding its clinical behaviour as well as treatment modalities and their results[6]. ADCC may occur at any age although in most cases the patients' age ranged from 24 to 78 years. The age of patients affected with major salivary gland tumours has been shown to be younger (mean 44 years) compared to the age of those who developed tumours of the minor glands (mean 54 years) and shows female predilection (F:M − 1.2:1). Pain is a common and important finding, occurring early in the course of the disease before there is a noticeable swelling[7].

ADCCs of minor salivary glands have been reported to have worse prognosis than those of the major salivary glands [8,9]. Tumours of minor salivary glands usually have the tendency to infiltrate extra glandular soft tissue and bone thereby allowing increased dissemination of the tumour. Lymph node involvement is uncommon (<5%) and is usually due to contiguous spread rather than lymphatic permeation or embolization(10).

Local recurrences occur despite combined treatment with surgery and radiotherapy. Some authors postulate that post- operative radiation may delay rather than prevents recurrences [11]. Many clinicians assume that "cure is never achieved in AdCC". Optimistic 5 year survival rates are occasionally reported (e.g.- 92 % in an Australian series)but 10 and 20 years survival rate continuously drops [12]

Possible treatment modalities available for the treatment of ADCC are surgery, radiotherapy, chemotherapy and combined therapy. It requires excision with the widest surgical margins possible as tumour cells extend well beyond the clinical and radiographic margins. Distant metastasis occurs in 25%-50% of patients and lung is the most common involved site[13].

The temporalis muscle flap has proven its versatility as a reconstructive tool in the oral and maxillofacial region. Maxillary defects caused by surgery or trauma results in facial disfigurement, functional limitation and psychological problems. Obturator has been the traditional method of rehabilitation but the variety of reconstructive options that are now available challenge the traditional view[14]. The temporalis muscle flap was first described by Lentz in 1895. The main limitation to this flap is the length of its pedicle, which prevents reconstruction of the tongue and the more central regions of the floor of the mouth and lower gingiva. The main complaints of patients with the temporalis muscle flap are the temporal depression. The temporalis muscle is an attractive options for maxillectomy reconstruction for many causes : the donor site and the defect is in same operative field and therefore the need for more complex free tissue transfer is avoided, there is considerable tissue available, the flap remains well vascularized and the flap can be used to correct the unilateral and bilateral defect[15]. As the technical aspects are rapidly improving, many surgeons now prefer microvascular flaps to reconstruct mid facial defects because they can be better adapted to the clinical needs of the patients and perfectly suits all the defects. Unfortunately however a microvascular flap is not appropriate for older people, patients with cardiovascular risk factors, patients who are to receive pre or post- operative radiotherapy may have a high risk of failure of the vascular anastomoses, with possible complications of flap necrosis and the need for another surgical procedure.

Another important aspect favouring the use of this flap after oncological procedures is the excellent viability of the flap that permits very early post-operative radiotherapy[16, 17, 18].

CONCLUSION

Surgery has been accepted as the primary treatment for minor salivary gland carcinoma of hard palate. Sufficient surgical excision with adequate margins is essential for a favourable outcome. Temporalis myofascial flap is a safe and reliable flap that can be used to reconstruct many surgical defects of misface. Temporalis myofascial flap is an alternative solution to free flap reconstruction and it should be always considered when planning an oncological procedure in head and neck area.

REFERENCES

1. Stell. PM. Adenoid cystic carcinoma. ClinOtolaryngol Allied Sci 1986 ; 11: 267-91.

2. Dockerty MB, Mayo CW. Primary tumours of submaxillary gland with special reference to mixed tumours. SurgGynecolObstet 1942;74:1033-45.

3.Vander Poorten V, Hunt J, Bradley PJ, et al. Recent trends in the management of minor salivary gland carcinoma. Head Neck 2014 ; 36 :444-55.

4. Van Weert S, Bloemena E , van der waal I , et al. Adenoid cystic carcinoma of the head and neck: a

 All rights reserved

single –center analysis of 105 consecutive cases over a 30 year period. Oral Oncol2013 ; 49: 824-

9. AnshulRai, NitinBhola, AbhayDatarkar, Rajeev Borle. Modified Weber- Fergusson incision with Borle's extension.British journal of Oral and Maxillofacial Surgery 48 (2010) e23-e24.

6. Grahne B, Lauren C, Holsti LR. Clinical and histological malignancy of adenoid cystic carcinoma. J Laryngol Otol. 1977; 91:743-9.

7. Neville BW, Damm D, Allen CM, Bouquot JE. Salivary gland pathology . In: Neville, editor. Oral and Maxillofacial Pathology . 3rd ed. Missouri:Saunders; 2009 : pp. 495-7.

8.Nascimento AG, Amaral AL, Prado LA. Kligerman J, Silveira TR. Adenoid cystic carcinoma of salivary glands: A study of 61 cases with clinicopathological correlation. Cancer. 1985;57:312-9.

9. Dal Maso MD, Lippi L. Adenoid cystic carcinoma of the head and neck : A clinical study of 37 cases. Laryngoscope. 1985;95:177-81.

10. Allen MS, Jr, Marsh WL, JrLymphnode involvement by direct extension in adenoid cystic carcinoma. Absence of classic embolic lymphnode metastasis. Cancer. 1976;38:2017-21

11. Katz TS , Mendenhall WM , Morris CG, Amdur RJ Hinerman RW , Villaret DB. Malignant tumors of the nasal cavity and paranasal sinuses . Head and neck 2002;24:821-9.

12. DeAngelis AF, Tsui A, Wiesenfeld D, Chandu A. Outcomes of patients with adenoid cystic carcinoma of the minor salivary glands. Int J Oral MaxillofacSurg 2011;40:710–4.

13. Laura D. Lung metastasectomy in Adenoid cystic carcinoma of salivary gland. Oral Oncol. 2005;41:890–4. [PubMed]

14. Brown JS, Rogers SN, McNally DN, Boyle M. Modified classification for the maxilloctomy defect. Head Neck 2000:17: 43–47.

15. Dexter WS, Jacob RF. Prosthetic rehabilitation after maxillectomy and temporalis flap reconstruction: a clinical report. J Prosthet Dent 2000: 283: 25–40.

16. Bakamjian V: A technique for primary reconstruction of the palate after radical maxillectomy for cancer. PlastReconstrSurg 31: 103e117,1963

17.Birt BD, Shyn A, Gruss JS: The temporalis muscle flap for head and neck reconstruction. J Otolaryngol 16: 179e184, 1987

18.Bradley P, Brockbank J: The temporalis muscle flap in oral reconstruction. J MaxillofacSurg 9: 139e145, 1981

All rights reserved